

# An elderly patient with Bickerstaff brainstem encephalitis: a case report

Islam MR<sup>a</sup>, Rahman T<sup>b</sup>, Khan MSH<sup>c</sup>, Islam MA<sup>d</sup>

### ABSTRACT

*Bickerstaff brainstem encephalitis is a rare autoimmune inflammatory disorder characterized by the triad of ophthalmoplegia, ataxia and decreased consciousness. It is considered as a variant of Miller Fisher syndrome and Guillain-Barré syndrome but differentiated by the presence of clinical features of central nervous system involvement. Here, we present a case of Bickerstaff's brainstem encephalitis with classical clinical features, suggestive radiological findings and positive anti-GQ1b antibody.*

**Key words:** Bickerstaff brainstem encephalitis, magnetic resonance imaging, brain, anti-GQ1b antibody.

*BIRDEM Med J 2024; 14(1): 53-56*

DOI: <https://doi.org/10.3329/birdem.v14i1.71021>

### INTRODUCTION

Bickerstaff brainstem encephalitis (BBE) was first described in 1957 by Bickerstaff et al.<sup>1</sup> This is a very rare entity that presents several clinical and immunological similarities with Guillain-Barré syndrome (GBS) and Miller-Fisher syndrome (MFS).<sup>2</sup> A Japanese survey estimated the annual incidence of BBE as 0.078/100 000, with an annual onset of 100 cases.<sup>3</sup> BBE is an immunologic disease characterized by the acute onset of ophthalmoplegia, ataxia and consciousness disturbance, mostly subsequent to infection. The IgG anti-GQ1b antibody is frequently present in the acute

phase of patients with BBE. Few clinical studies with a large number of patients with BBE have been reported because it is a rare disease.<sup>4</sup> A nationwide survey of the Japanese population reported the epidemiologic features and nosological position of BBE among brainstem encephalitis. They proposed the criteria for the diagnosis of BBE, in which BBE was divided into 2 categories (i.e., definite and probable). Definite BBE, which is defined as having typical clinical features and positive anti-GQ1b antibody, showed rather homogeneous characteristics compared with probable BBE.<sup>3</sup> Here, we report an adult patient of BBE with classical clinical features, suggestive magnetic resonance imaging (MRI) of brain findings and positive anti-GQ1b antibody.

---

### Author information

- Md. Rashedul Islam, Associate Professor, Department of Neurology, BIRDEM General Hospital, Dhaka, Bangladesh.
- Tanbin Rahman, Assistant Professor (Medicine), Anwer Khan Modern Medical College Hospital, Dhaka, Bangladesh.
- Mohammad Sakhawat Hossen Khan, Registrar, Department of Neurology, BIRDEM General Hospital, Dhaka, Bangladesh.
- Md. Azharul Islam, MD Resident, Department of Gastroenterology, BIRDEM General Hospital, Dhaka, Bangladesh.

**Address of correspondence:** Md. Rashedul Islam, Associate Professor, Department of Neurology, BIRDEM General Hospital, Dhaka, Bangladesh. Email: [rashed2k2001@yahoo.com](mailto:rashed2k2001@yahoo.com)

**Received:** December 21, 2023

**Revision received:** December 25, 2023

**Accepted:** December 26, 2023

### CASE REPORT

A 70-year-old non-diabetic, normotensive gentleman presented with drowsiness, dysarthria, diplopia and ataxia for 2 days. He subsequently developed quadriparesis. He had history of diarrhoea for 7 days prior to this illness. Physical examination of the nervous system revealed bilateral ophthalmoplegia, dysarthria, spastic quadriparesis, exaggerated bilateral deep tendon reflexes with positive bilateral plantar extensor response. He had ataxia during examination of gait. He had episodes of drowsiness throughout the day and his Glasgow Coma Scale score varied between 15/15 and 12/15. The patient appeared confused during conversation and was occasionally disorientated to time,

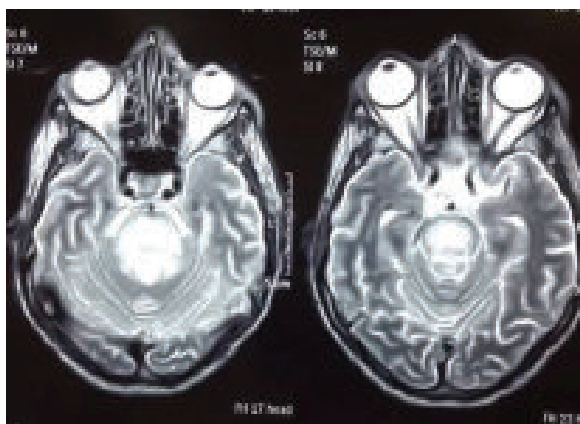
**Table I.** Proposed clinical diagnostic criteria for BBE, MFS and GBS

Syndrome	Diagnostic criteria
BBE	Ophthalmoplegia and ataxia with disturbed consciousness and/or pyramidal signs
MFS	Acute ophthalmoplegia and ataxia with areflexia or hyporeflexia
GBS	Acute symmetrical limb weakness and areflexia

BBE, Bickerstaff's brainstem encephalitis; MFS, Miller-Fisher syndrome; GBS, Guillain-Barré syndrome.

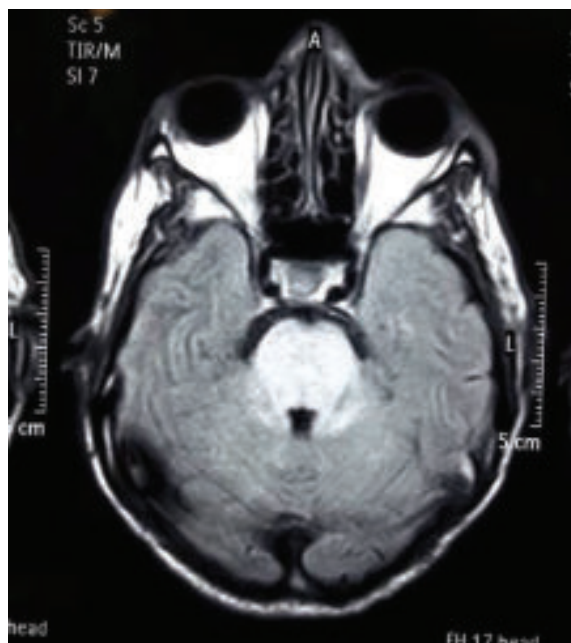
place and/or person. He had no headache, neck stiffness or photophobia.

His complete blood count showed, white cell count (WCC)  $7.4 \times 10^9/L$  and neutrophil count  $4.1 \times 10^9/L$ ; ESR was 16 mm/hour. C reactive protein (CRP) was 4.2 mg/L. CSF study showed that protein was 0.86 g/L (normal range 0.08–0.43 g/L), cell number was: 2, 100% lymphocyte, red blood cell count was 0. Cerebrospinal fluid (CSF) and serum anti-GQ1b antibody was positive. An Indian ink stain was negative. MRI of brain (Figures 1 and 2) showed hyperintense signal changes involving brainstem that was suggestive of encephalitis. CSF panel for viral serology was found to be negative. Vasculitis screening including ANA, C-ANCA, p-ANCA were negative. Chest X-ray, ultrasonography of whole abdomen, prostate-specific antigen (PSA), carcinoembryonic antigen (CEA), CA19-9 were done to exclude any underlying malignancy considering a possibility of paraneoplastic encephalitis.



**Figure 1.** MRI of brain (T2 sequence) showing hyperintense signal changes involving brain stem

Differential diagnosis of brainstem viral encephalitis and MFS were initially considered. However, CSF study findings and a negative viral screen made a diagnosis



**Figure 2.** MRI of brain (FLAIR sequence) showing hyperintense signal changes involving brain stem

of encephalitis unlikely. The brisk reflexes were inconsistent with MFS. So, a diagnosis of BBE was made based on the clinical features of ataxia, ophthalmoplegia and impaired consciousness after preceding illness of infection, suggestive radiological findings and positive anti-GQ1b. He was given intravenous immunoglobulin for 5 days followed by physiotherapy and rehabilitation. The patient's symptoms gradually improved and he was able to start walking on his own. His limb collateral movement was significantly better than before, his eye movement was normal. After 3 months, the patient could walk without assistance and his speech also returned to normal.

## DISCUSSION

BBE is an autoimmune disorder that falls under the same spectrum as MFS and GBS.<sup>5</sup> These are post infectious

disorders that share common clinical traits such as ataxia and ophthalmoplegia. Patients frequently exhibit prodromal upper respiratory infection/diarrheal illness, CSF albumino cytological dissociation, and serum IgG antibody to ganglioside GQ1b3.<sup>6</sup> This is classified as a central nervous system (CNS) disease; whereas, GBS and MFS are peripheral nervous system (PNS) disorders.<sup>5</sup> The etiology of the disease is still unclear. Infectious etiology is considered as an antecedent history of upper respiratory tract infection or diarrhoea. MRI of brain supports the diagnosis of BBE as abnormal findings are present in only 30% of patients.<sup>5</sup> Typical findings of BBE include hyperintense changes brainstem in T2/FLAIR sequence of MRI<sup>7</sup>, which were evident in our case.

Bickerstaff differentiated BBE from MFS by the presence of disturbed consciousness, which is only a feature in BBE. As a result, debate ensued as to the nature of the nerve damage in BBE, which was regarded by Bickerstaff as a brainstem viral infection and by others as an autoimmune polyneuritis.<sup>8</sup> A proposed clinical diagnostic criterion is set for the purpose of distinguishing BBE, MFS and GBS (Table I). In general, patients are classified as having BBE rather than MFS if there is evidence of central involvement like decreased consciousness or long tract signs, such as clonus, spasticity and hyper-reflexia. A study was undertaken to clarify the neurological features of 62 cases of BBE. CNS manifestations included disturbed consciousness (drowsiness 45%; stupor, semicomatose or coma 29%), hyperreflexia (34%), Babinski's sign (40%) and deep sensory impairment (16%). Other common neurological features included facial weakness, bulbar palsy and nystagmus. Although the pathophysiology of BBE is not yet fully understood, research has shed light on possible underlying mechanisms.<sup>9</sup>

Another study was undertaken to explain the phenotypic differences between MFS and BBE, based on the effects of sera in relation to the blood-brain barrier. Sera from patients with BBE disrupted the blood-brain barrier and were associated with increased secretion of matrix metalloproteinase secreted by human brain microvascular endothelial cells (BMECs), whereas sera from patients with MFS had no effect on BMECs.<sup>10</sup> These findings may explain the CNS manifestations in patients with BBE. Serum from patients with GBS, MFS and BBE has been shown to contain antibodies against

gangliosides.<sup>8</sup> BBE and MFS are associated with anti-GQ1b antibodies, whereas GBS is associated predominantly with anti-GM1 antibodies. Subsequently, it has been suggested that the three disorders form part of a continuous clinical spectrum, involving the PNS and CNS. Not all cases of BBE are anti-GQ1b positive; the serum GQ1b IgG antibody-positive rate in BBE is reported as 70%.<sup>9</sup> Our patient was anti-GQ1b positive with ophthalmoplegia and brisk reflexes. A recent report on BBE suggested that this may instead represent CNS pathology, namely an immune-mediated inflammatory disease affecting the white matter of the brain and spinal cord.<sup>11</sup> In several cases of BBE, antecedent pathogens have been identified supporting the evidence that antiganglioside antibodies work via molecular mimicry with infectious agents. They include Herpes simplex virus, Cytomegalovirus, Epstein-Barr virus, Varicella-Zoster virus, Measles virus, Salmonella typhi, Mycoplasma pneumonia and Campylobacter jejuni enteritis.<sup>9</sup> We could not search the pathogen extensively due to lack of investigation facilities.

A definitive treatment for BBE has yet to be found. The established treatment is intravenous immunoglobulin and plasmapheresis, although more clinical trials are required to determine its effectiveness. A paper was published reviewing the clinical aspects of BBE based on a nationwide survey in Japan. It concluded that BBE consisted of typical and atypical cases; typical BBE was associated with a good recovery, whereas atypical BBE was characterized by delayed recovery and abnormal CSF and brain MRI findings.<sup>3</sup> We treated our patient with intravenous immunoglobulin with good functional outcome.

**Authors' contribution:** MRI compiled the case and wrote the report. TR reviewed literatures. MSHK searched the references. All authors read and approved final draft for publication.

**Consent:** Informed written consent was taken from the patient for publication of this case report and accompanying images.

**Conflicts of interests:** Nothing to declare.

## REFERENCES

1. Michev A, Musso P, Foadelli T, Trabatti C, Lozza A, Franciotta D, et al. Bickerstaff brainstem encephalitis and overlapping Guillain-Barré syndrome in children: report of two cases and review of the literature. *Eur J Paediatr Neurol* 2019;23(1):43-52.

2. Battaglia F, Franques J, Somma-Mauvais H, Roche PH. Tableau d'encéphalite de Bickerstaff et hypertension intracrânienne. *Rev Neurol (Paris)* 2011;167(2):164-8.
3. Koga M. Bickerstaff brainstem encephalitis: epidemiology, diagnosis, and therapy. *Nihon Rinsho* 2013;71:898-903.
4. Yoshikawa K, Kuwahara M, Morikawa M, Kusunoki S. Bickerstaff brainstem encephalitis with or without anti-GQ1b antibody. *Neurol Neuroimmunol Neuroinflamm* 2020 Sep 15;7(6):e889.
5. Doudier B, Rovey C, Rossi P, Feuillet L, Brouqui P. Bickerstaff's brainstem encephalitis: a case report. *Med Mal Infect* 2007 Apr;37(4):234-6.
6. Park JY, Ko KO, Lim JW, Cheon EJ, Yoon JM, Kim HJ. A pediatric case of Bickerstaff's brainstem encephalitis. *Korean J Pediatr* 2014 Dec;57(12):542-5.
7. Manjunath MA, Kariyappa P, Ramabhata S, Kittagaly PA, Shankar K. Bickerstaff Brainstem Encephalitis - A Serious Disease with a Favourable Outcome. *Pediatr Oncall J* 2019;16: 86-7.
8. Ropper AH. The CNS in Guillain-Barré syndrome. *Arch Neurol* 1983;40:397-8.
9. Odaka M, Yuki N, Hirata K. Anti-GQ1b IgG antibody syndrome: clinical and immunological range. *J Neurol Neurosurg Psychiatry* 2001;70:50-5.
10. Saito K, Shimizu F, Koga M, Sano Y, Tasaki A, Abe M, et al. Blood-brain barrier destruction determines Fisher/Bickerstaff clinical phenotypes: an in vitro study. *J Neurol Neurosurg Psychiatry* 2013 Jul;84(7):756-65.
11. Roos RP, Soliven B, Goldenberg F, Badruddin A, Baron JM. An elderly patient with Bickerstaff brainstem encephalitis and transient episodes of brainstem dysfunction. *Arch Neurol* 2008 Jun;65(6):821-4.